

## Review

# Distal protection devices during percutaneous coronary and carotid interventions

Panayotis Fasseas, James L Orford, Ali E Denktas and Peter B Berger

Division of Cardiovascular Diseases, Mayo Clinic, Rochester, Minnesota, USA

Correspondence: Peter Berger, berger.peter@mayo.edu

Published online: 23 November 2001

*Curr Control Trials Cardiovasc Med* 2001, **2**:286-291

© 2001 BioMed Central Ltd (Print ISSN 1468-6708; Online 1468-6694)

### Abstract

Distal embolization of particulate matter complicates percutaneous coronary and peripheral interventions more often than had been recognized until recently. A number of distal protection devices are under development. The PercuSurge GuardWire™ is a balloon occlusion thrombectomy device approved by the United States Food and Drug Administration for saphenous vein graft intervention. A number of filter devices utilize an expandable filter mounted on the angioplasty guidewire to facilitate entrapment of particles and safe removal. The Parodi Anti-Emboli System™ is an example of a catheter occlusion device that establishes protection by reversing blood flow in the target vessel.

**Keywords** angioplasty, distal protection device, procedural myocardial infarction

Distal embolization of particulate matter, including plaque debris and thrombus, complicate percutaneous coronary and peripheral interventions more often than had been recognized until recently. This often results in diminished blood flow to the distal vascular bed and is associated with periprocedural end-organ ischemia and infarction, as demonstrated by perfusion defects and serum cardiac enzyme elevation [1,2]. Periprocedural myocardial infarction (MI) is associated with a worse prognosis, particularly when it is large, which is most clearly demonstrated in saphenous vein bypass graft interventions. This was demonstrated by Hong *et al.* who studied 1056 consecutive patients with angiographically successful percutaneous coronary intervention of 1693 SVG lesions [3]. One-year mortality was significantly increased in patients with periprocedural creatine kinase-MB elevation, even among patients without any apparent procedure or in-hospital complication.

Distal embolization of large particles at the time of balloon inflation or stent deployment may obstruct large, epicardial vessels, but the scope of the problem includes microvascular

obstruction due to very small particles, as little as 15–100 microns, that may result in microinfarcts and left ventricular dysfunction [4]. It is likely that mechanical microvascular obstruction is commonly aggravated by secondary spasm and edema due to release of humoral agonists by platelets, and endothelial injury and dysfunction. Limited therapeutic success has been reported from observational studies involving the use of calcium channel blockers, adenosine, and sodium nitroprusside [5]. However, the success of these medical interventions is most commonly defined by angiographic resolution of the “no-reflow” phenomenon (an acute reduction in coronary flow less than Thrombolysis in Myocardial Infarction [TIMI] 2 in the absence of dissection, thrombus, spasm, or high-grade residual stenosis at the original target lesion). A beneficial effect on hard clinical endpoints has been more difficult to prove.

### Glycoprotein IIb/IIIa inhibitors and percutaneous coronary intervention

Glycoprotein (GP) IIb/IIIa inhibitors reduce not only procedural infarctions, but also major adverse clinical events in

FDA = United States Food and Drug Administration; GP = glycoprotein; MI = myocardial infarction; PAES = Parodi Anti-Emboli System; US = United States.

GUARD = Saphenous Vein Graft Intervention using AngioGuard for Reduction of Distal Embolization trial; SAFE = Saphenous Vein Graft Angioplasty Free of Emboli study; SAFER = Saphenous Vein Graft Angioplasty Free of Emboli, Randomized trial; SAPHIRE = The Study of Angioplasty with Protection in Patients at High Risk for Endarterectomy; TIMI = Thrombolysis in Myocardial Infarction.

**Table 1****Distal protection devices that are available or under development**

| Device type                | Device name               | Manufacturer  |
|----------------------------|---------------------------|---|
| Balloon occlusion devices  | PercuSurge GuardWire      | Medtronic, Santa Rosa, CA, USA                        |
| Filter devices             | AngioGuard                | Cordis Corp., Minneapolis, MN, USA                    |
|                            | FilterWire EX             | Boston Scientific Corp., Natick, MA, USA              |
|                            | Mednova Neuroshield       | Mednova Inc., Galway, Ireland                         |
|                            | AccuNet                   | Guidant Corp., Indianapolis, IN, USA                  |
| Catheter occlusion devices | Parodi Anti-Emboli System | ArteriA Medical Science, Inc., San Francisco, CA, USA |

patients undergoing percutaneous coronary intervention. The benefit is thought to be, in part, due to a reduction in the incidence of ischemic complications, which is likely to be secondary to prevention of platelet aggregation, thrombus formation, and distal embolization, in native coronary arteries [6]. These benefits, however, have been apparent in subset analyses of clinical trials, or in observational studies designed to specifically assess their efficacy in saphenous vein graft interventions. Despite suggestion of benefit as measured by surrogate angiographic endpoints, there is no evidence of a consistent and sustained meaningful clinical benefit [7,8]. The likely explanation for this apparent lack of benefit in vein graft interventions, when GP IIb/IIIa inhibitors clearly reduce procedural infarctions by approximately 50%, is the difference in the composition of the embolic material. Distal embolization during saphenous vein graft intervention is predominantly due to soft acellular atheromatous material typically found under the fibrous cap (cholesterol clefts, lipid-rich macrophages, and fibrin material) that occurs in >10% of interventions on vein grafts that are more than three years old [9]. Independent predictors of distal embolization include diffuse degeneration and large plaque volume rather than thrombus, and angiography studies have found that vein graft friability, rather than thrombus, was a stronger predictor of distal embolization and 'no-reflow' [9,10]. The relative contribution of platelet aggregates or atheromatous material to distal embolization and vessel occlusion in native coronary arteries is unclear. Despite these aforementioned beneficial effects of aggressive platelet inhibition during percutaneous coronary intervention, however, further reductions in distal embolization remains an important goal, particularly in the acute coronary syndromes.

### Percutaneous carotid interventions

Percutaneous carotid interventions are frequently complicated by embolization [11]. Jordan *et al.* and others have demonstrated that there is Doppler evidence of microembolization during almost all carotid stenting procedures [12]. The precise clinical significance of this phenomenon remains unclear, since the brain appears to have a surprising tolerance for microembolization in the acute setting. No one has yet linked

these emboli to adverse clinical events. However, even small plaque fragments less than 200 microns may cause neuronal ischemia at later time points, and periprocedural microemboli may be responsible for both stroke and more subtle neurologic dysfunction in late follow-up [13,14]. Carotid angioplasty and stenting is associated with a perioperative stroke rate exceeding 3% in most series, largely due to emboli. Additionally, this embolic complication continues to limit the applicability of percutaneous revascularization in patients who are suitable for surgical carotid endarterectomy [15].


### Balloon occlusion devices: PercuSurge GuardWire

A number of distal protection devices that aim to reduce or eliminate distal embolization during percutaneous coronary and carotid interventions are under development (Table 1).

Only one such device has already been approved for use by the United States Food and Drug Administration (FDA). The PercuSurge GuardWire (Medtronic, Santa Rosa, CA, USA) is an occlusion thrombectomy device that consists of a wire containing a central lumen that communicates with a low-pressure distal occlusion balloon incorporated into the tip (Fig. 1). The wire serves as both the angioplasty guidewire and provides protection from distal embolization. An inflation device allows controlled expansion and sizing of the occlusion balloon in the treated vessel. An aspiration catheter is used to remove the debris from the treated vessel before the balloon is deflated and antegrade flow in the treated vessel is restored.

The Saphenous Vein Graft Angioplasty Free of Emboli (SAFE) study evaluated the safety and feasibility of this device [16]. Initial encouraging results in the European and Canadian registries were confirmed in the Saphenous Vein Graft Angioplasty Free of Emboli, Randomized (SAFER) trial conducted in the United States (US) [17]. The SAFER trial was conducted at 47 sites and enrolled 659 patients undergoing saphenous vein graft percutaneous coronary intervention. Inclusion criteria were stenoses of 50–99% in saphenous vein grafts 3–6 mm in diameter, more than 5 mm from the ostium and 20 mm from

Figure 1



The PercuSurge GuardWire balloon occlusion device and export catheter.

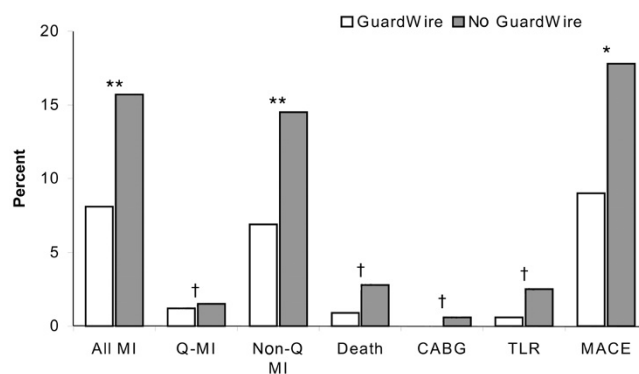
the distal anastomosis, and at least TIMI 1 flow at baseline. Exclusion criteria included acute MI, ejection fraction <25%, creatinine >2.5 mg/dL (unless on hemodialysis), and planned use of an atherectomy device. The primary endpoint was the occurrence of major adverse clinical events at 30 days, including death, MI, emergency bypass surgery, and repeat target vessel revascularization.

Pre-specified secondary endpoints were the frequency with which TIMI 3 flow was achieved, and clinically apparent no-flow occurred. The GuardWire was superior to 'standard care' (Figs 2 and 3). There was a 50% relative reduction in cumulative 30-day major adverse cardiac events (17.8% to 9.0%,  $P=0.001$ ), a 68% relative reduction in mortality (2.8% to 0.9%,  $P=0.086$ ), and a 49% relative reduction in MI (17.3% to 8.8%,  $P=0.003$ ). The trial was stopped early by the data safety monitoring board, and the manufacturer promptly secured FDA approval.

Interestingly, although GP IIb/IIIa inhibitors were used in >60% of all patients, predominantly before intervention, major adverse clinical events were more common amongst those receiving the drug. Since this was a non randomized, retrospective analysis, no conclusions about a potentially beneficial (or deleterious) affect can be made. However, it is apparent that the reduction in major adverse clinical events in the GuardWire arm was independent of the use of GP IIb/IIIa inhibitors.

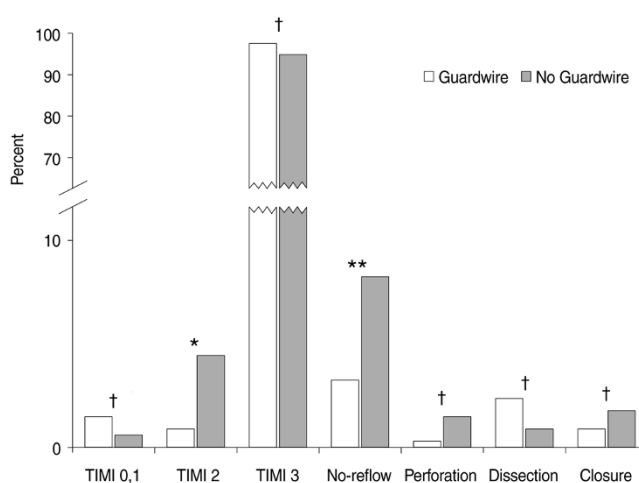
Similarly, the feasibility and safety of carotid angioplasty and stenting using the PercuSurge GuardWire system has been determined [10]. Technical success was reported in a series of 48 high-risk patients (39 men, mean age  $69.1 \pm 8$  years) with 53 internal carotid artery stenoses. Mean cerebral flow occlusion time was  $346 \pm 153$  seconds during predilation

Figure 2



Major adverse cardiac events that had occurred by 30 days in the SAFER trial. All MI, all myocardial infarction; CABG, coronary artery bypass graft surgery; MACE, major adverse cardiac events at 30 days; non-Q MI, non-Q-wave myocardial infarction; Q-MI, Q-wave myocardial infarction; TLR, target lumen revascularization. \* $P=0.001$ , \*\* $P=0.003$ , † $P$  = not significant.

Figure 3



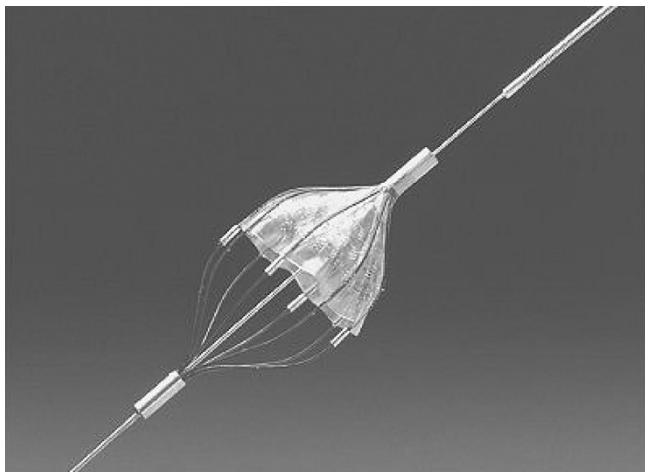
The frequency of secondary endpoints in the SAFER trial. Closure refers to abrupt vessel closure. TIMI, Thrombolysis in Myocardial Infarction. \* $P=0.004$ , \*\* $P=0.005$ , † $P$  = not significant.

and  $303 \pm 143$  seconds during stent placement. One immediate neurological complication (transient amaurosis fugax) was documented in a patient who had a surgical anastomosis between the external and internal carotid arteries.

### Filter Devices

#### AngioGuard™

A second 'class' of distal protection devices under development and currently undergoing clinical investigation are the filter devices. AngioGuard (Cordis Corp., Minneapolis, MN, USA) is an example of such a device that has recently


**Figure 4**

The AngioGuard guidewire filter device.

received approval for marketing in Europe. AngioGuard's technology incorporates an angioplasty guidewire with a filter that expands to 6 mm and is placed distal to the target lesion to capture and retrieve embolic debris (Fig. 4). At the end of the procedure, the filter is collapsed, trapping the particulate matter and facilitating removal from the artery.

The AngioGuard filter has multiple, 100 micron, laser-drilled holes that allow perfusion during device deployment. It has been proposed that this is a major advantage of filter devices. In contrast, the balloon occlusion devices result in complete cessation of antegrade flow for as long as it takes to treat the vessel and aspirate the debris (typically 2–3 minutes in the hands of experienced operators) [9,15]. This is a critical clinical consideration in patients with reduced left ventricular function or in patients in whom the treated artery supplies a large amount of myocardium. Conversely, it has been proposed that incomplete vessel occlusion with the filter devices allows passage of debris through the holes of the filter devices. Indeed, analysis of debris retrieved by the balloon occlusion thrombectomy device in the SAFE trial device found that 80% of the particulate matter was less than 100 microns in diameter. The clinical significance of such small embolic particles is unclear, and difficult to resolve since the completeness of debris entrapment by any distal protection device is impossible to determine in clinical practice.

The initial experience with the AngioGuard filter device is promising. A phase I trial in 33 consecutive lesions (in 31 patients) of the internal carotid artery documented successful deployment of the filter in 82% of the lesions. Debris that might have been expected to result in distal vessel occlusion was collected in 80% of cases. This technology is currently under investigation in the US for both carotid and coronary percutaneous interventions in appropriately sized trials.

**Figure 5**


The FilterWire guidewire filter device and retrieval catheter.

The Study of Angioplasty with Protection in Patients at High Risk for Endarterectomy (SAPPHIRE) is examining the benefits of the AngioGuard device among 720 patients undergoing carotid artery stenting in a randomized trial versus 'standard care' (no distal protection device) [18]. The Saphenous Vein Graft Intervention using AngioGuard for reduction of Distal Embolization (GUARD) trial is also ongoing and will determine the efficacy of this device in a study population analogous to the SAFER trial. The appropriateness of continuing such trials with a control arm without distal protection has been a source of controversy. The use of the distal protection device reduces adverse events by 50% (the PercuSurge device) and is approved for use and currently available. As a result, the control arms of these trials are now being reconsidered.

#### FilterWire EX™

The FilterWire EX (Boston Scientific, Natick, MA, USA) is another filter device currently under clinical investigation (Fig. 5). Similar to the AngioGuard, it is a low-profile (<3.5 French) filter mounted on a 0.014 inch angioplasty wire with pore holes of 80 microns that permit antegrade blood flow while providing distal protection. The filter design is characterized by an off-center position and 'fish-mouth' opening, and can be retracted into any standard angioplasty balloon. A radiopaque nitinol framework provides filter support and facilitates fluoroscopic visualization. Initial corporate reports of feasibility, safety, and clinical efficacy are promising. A complication rate of 7% was reported during 61 saphenous vein graft interventions (4 non-Q wave MIs). This compares favorably with historical control rates of >10%. Equally impressive, unpublished results in small numbers of patients undergoing carotid, native coronary artery, and renal percutaneous intervention, will hopefully result in randomized, controlled clinical trials to clarify these preliminary results.

Figure 6



The Parodi anti-embolization catheter.

### MedNova Neuroshield™

The MedNova NeuroShield (MedNova Inc., Galway, Ireland) is a filter that is mounted on the distal tip of a 0.014 inch guidewire, and its use requires both a delivery catheter and a retrieval catheter. The filter contains a pre-shaped nitinol expansion system that facilitates fluoroscopic visualization, accurate deployment, and wall apposition. The filter guidewire is placed within the delivery catheter and is passed through the target stenosis, the delivery catheter is withdrawn, the filter is deployed, and after completion of the vascular intervention (angioplasty, stenting, etc.) the retrieval catheter is used to envelop the filter. Then, the entire device and its embolic contents are withdrawn.

### Catheter Occlusion Devices

The Parodi Anti-Emboli System (PAES; ArteriA Medical Science, Inc., San Francisco, CA, USA) is a guiding catheter with an occlusion balloon attached at its distal end (Fig. 6). The PAES establishes protection by reversing blood flow in the target vessel [19,20]. In the carotid arteries, the system works by occluding the common carotid, which creates a negative pressure gradient distal to the balloon occlusion and establishes retrograde flow in the internal carotid artery. The external carotid is also occluded to avoid flow traveling from the external one back up the internal one. This system establishes protection without the risk of disruption of the target lesion, thereby reducing the risk of embolic stroke during device deployment prior to percutaneous intervention.

The company reports performance of 200 cases worldwide (in Italy, Argentina, New Zealand, Australia, Germany, Belgium, France, and Sweden), with 100% successful deployment and no ipsilateral embolic events. Two patients suffered an intracranial hemorrhage, one patient died following a periprocedural MI, one patient had a contralateral embolic event during a coronary artery bypass graft procedure

performed at the same time, and one patient had a minor contralateral ischemic stroke. A small Investigational Device Exemption (IDE) clinical study in the US is planned.

### Conclusion

There remains great controversy about the clinical significance of the procedural infarctions that occur in approximately 10% of percutaneous interventions in the native coronary arteries, and particularly the small subclinical infarctions that occur during otherwise successful procedures. There is nothing controversial or subtle, however, about a great many of the embolic infarctions that occur during vein graft or carotid interventions. Neither the approved device nor the devices under investigation are, at present, perfect. Doubtless all will undergo improvements in the future, and offer hope for further increasing the safety of high-risk percutaneous interventions.

### Competing interests

None declared.

### References

1. Califf RM, Abdelmeguid AE, Kuntz RE, Popma JJ, Davidson CJ, Cohen EA, Kleiman NS, Mahaffey KW, Topol EJ, Pepine CJ, Lipicky RJ, Granger CB, Harrington RA, Tardiff BE, Crenshaw BS, Bauman RP, Zuckerman BD, Chaitman BR, Bittl JA, Ohman EM: **Myonecrosis after revascularization procedures.** *J Am Coll Cardiol* 1998, **31**:241-251.
2. Koch KC, vom Dahl J, Kleinhans E Koch KC, vom Dahl J, Kleinhans E, Klues HG, Radke PW, Ninnemann S, Schulz G, Buell U, Hanrath P: **Influence of a platelet GPIIb/IIIa receptor antagonist on myocardial hypoperfusion during rotational atherectomy as assessed by myocardial Tc-99m sestamibi scintigraphy.** *J Am Coll Cardiol* 1999, **33**:998-1004.
3. Hong MK, Mehran R, Dangas G, Mintz GS, Lansky AJ, Pichard AD, Kent KM, Satler LF, Stone GW, Leon MB: **Creatine kinase-MB enzyme elevation following successful saphenous vein graft intervention is associated with late mortality.** *Circulation* 1999, **100**:2400-2405.
4. Hori M, Gotoh K, Kitakaze M, Hori M, Gotoh K, Kitakaze M, Iwai K, Iwakura K, Sato H, Koretsune Y, Inoue M, Kitabatake A, Kamada T: **Role of oxygen-derived free radicals in myocardial edema and ischemia in coronary microvascular embolization.** *Circulation* 1991, **84**:828-840.
5. Piana RN, Paik GY, Moscucci M, Cohen DJ, Gibson CM, Kugelmass AD, Carrozza JP Jr, Kuntz RE, Baim DS: **Incidence and treatment of 'no-reflow' after percutaneous coronary intervention.** *Circulation* 1994, **89**:2514-2518.
6. Lincoff AM, Califf RM, Topol EJ: **Platelet glycoprotein IIb/IIIa receptor blockade in coronary artery disease.** *J Am Coll Cardiol* 2000, **35**:1103-1115.
7. Mathew V, Grill DE, Scott CG, Grantham JA, Ting HH, Garratt KN, Holmes DR Jr: **The influence of abciximab use on clinical outcome after aortocoronary vein graft interventions.** *J Am Coll Cardiol* 1999, **34**:1163-1169.
8. Mak KH, Challapalli R, Eisenberg MJ, Anderson KM, Califf RM, Topol EJ: **Effect of platelet glycoprotein IIb/IIIa receptor inhibition on distal embolization during percutaneous revascularization of aortocoronary saphenous vein grafts. EPIC Investigators. Evaluation of IIb/IIIa platelet receptor antagonist 7E3 in Preventing Ischemic Complications.** *Am J Cardiol* 1997, **80**:985-988.
9. Webb JG, Carere RG, Virmani R, Baim D, Teirstein PS, Whitlow P, McQueen C, Kolodgie FD, Buller E, Dodek A, Mancini GB, Oesterle S: **Retrieval and analysis of particulate debris after saphenous vein graft intervention.** *J Am Coll Cardiol* 2000, **34**:468-475.
10. Henry M, Amor M, Henry I, Klonaris C, Chati Z, Masson I, Kownator S, Luizy F, Hugel M: **Carotid stenting with cerebral protec-**

- tion: First clinical experience using the PercuSurge Guard-Wire system.** *J Endovasc Surg* 1999, **6**:321-331.
11. Liu MW, Douglas JS Jr, Lembo NJ, King SB 3rd: **Angiographic predictors of a rise in serum creatinine kinase (distal embolization) after balloon angioplasty of saphenous vein coronary artery bypass grafts.** *Am J Cardiol* 1993, **72**:514-517.
  12. Jordan WD Jr, Voellinger DC, Doblar DD, Plyushcheva NP, Fisher WS, McDowell HA: **Microemboli detected by transcranial Doppler monitoring in patients during carotid angioplasty versus carotid endarterectomy.** *Cardiovasc Surg* 1999, **7**:33-38.
  13. Rapp JH, Pan XM, Sharp FR, Shah DM, Wille GA, Velez PM, Troyer A, Higashida RT, Saloner D: **Atheroemboli to the brain: size threshold for causing acute neuronal cell death.** *J Vasc Surg* 2000, **32**:68-76.
  14. Akerstaff RG, Moons KG, van de Vlasakker CJ, Moll FL, Vermeulen FE, Algra A, Spencer MP: **Association of intraoperative transcranial doppler monitoring variables with stroke from carotid endarterectomy.** *Stroke* 2000, **31**:1817-1823.
  15. Roubin GS, New G, Iyer SS, Vitek JJ, Al-Mubarak N, Liu MW, Yadav J, Gomez C, Kuntz RE: **Immediate and late clinical outcomes of carotid artery stenting in patients with symptomatic and asymptomatic carotid artery stenosis: a 5-year prospective analysis.** *Circulation* 2001, **103**:532-537.
  16. Grube E, Webb J, for the SAFE study group: **The SAFE study. Multicenter evaluation of a protection catheter system for distal embolization in coronary venous bypass grafts (SVG's).** *J Am Coll Cardiol* 1999, **33**:37A.
  17. Baim DS: **SAFER: A prospective, multi-center randomized trial of distal protection in patients undergoing percutaneous intervention of saphenous vein grafts.** *Presented at Transcatheter Cardiovascular Therapeutics 2000.* Washington, D.C., October 17-22, 2000.
  18. Hobson RW II: **Status of carotid angioplasty and stenting trials.** *J Vasc Surg* 1998, **27**:791.
  19. Ohki T, Parodi J, Veith FJ, Bates M, Bade M, Chang D, Mehta M, Rabin J, Goldstein K, Harvey J, Lipsitz E: **Efficacy of a proximal occlusion catheter with reversal of flow in the prevention of embolic events during carotid artery stenting: An experimental analysis.** *J Vasc Surg* 2001, **33**:504-509.
  20. Parodi JC, La Mura R, Ferreira LM, Mendez MV, Cersosimo H, Schonholz C, Garelli G: **Initial evaluation of carotid angioplasty and stenting with three different cerebral protection devices.** *J Vasc Surg* 2000, **32**:1127-1136.